

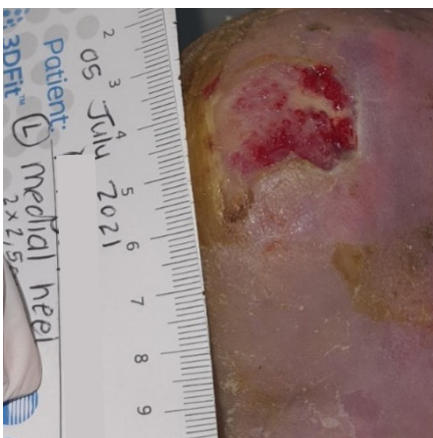
## Pressure sore in lower limb of patient with a peripheral neuropathy

### Patient information:

An 83 year old male with peripheral neuropathy and history of previous bladder cancer, presented with a pressure sore on left medial heel. The wound was macerated, infected with a large amount of exudate.

### Description of initial treatment:

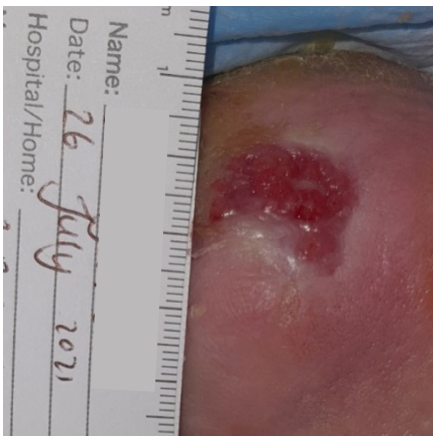At presentation, standard treatment of care was commenced – enzymatic debridement was done, antibacterial dressings were applied and infection was treated with oral antibiotic, and the large amount of exudate was managed with foam dressings. The patient had moderate pain – 4/10.



### Treatment with AmnioRederm

#### Day 0 [05.07.2021]

AmnioRederm was first applied to the wound on 05.07.2021. The wound size was 2,5cm x 2,0cm. An antimicrobial was applied with the AmnioRederm as the patient was at risk of infection. A foam dressing was also applied.

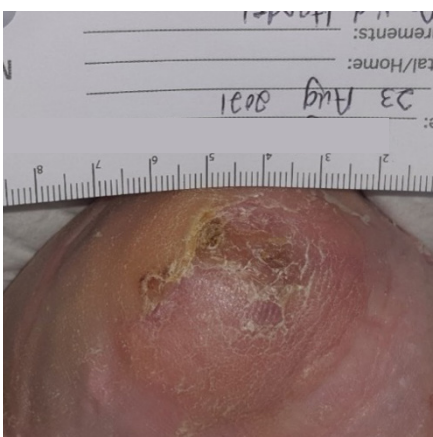

#### Day 21 [26.07.2021]

The patient was seen weekly and AmnioRederm was applied weekly with a covering foam dressing. The wound progressed well with an increase in granulation, decrease in exudate, improvement in margins and advancement of edges.

By Day 21, the wound was 2,2cm x 1,4cm in size.

The patient had no pain at this point and there was no infection in the wound.



#### Day 49 [23.08.2021]

Continuous improvement was seen with increasing health of the wound bed and epithelialisation. AmnioRederm was applied at every weekly visit.

The wound was completely closed by Day 49 [7 weeks].

Seven applications of AmnioRederm, with a foam dressing, were done in total.

---

### Summary of outcomes

Time to complete healing was 7 weeks with 7 applications of AmnioRederm. The patient's pain decreased, and infection cleared within the first week and did not reoccur during the treatment period. Granulation, a decrease in exudate and epithelisation progressed consistently throughout treatment until complete closure of the wound.

### Acknowledgement and thanks to:

Sr Yolandi de Hoog  
Wound Care Specialist  
Plettenberg Bay